

Severe Vascular Complication after Implantation of a Three-Piece Inflatable Penile Prosthesis

Federico Deho', MD,* Gerard D. Henry, MD,† Enrico M. Marone, MD,‡ Antonino Sacca', MD,* Roberto Chiesa, MD,‡ Patrizio Rigatti, MD,* and Francesco Montorsi, MD*

*Department of Urology, Vita-Salute University, Milan, Italy; †Regional Urology, Shreveport, Louisiana, USA; ‡Department of Vascular Surgery, Vita-Salute University, Milan, Italy

DOI: 10.1111/j.1743-6109.2008.01012.x

ABSTRACT

We report a case of acute arterial ischemia and deep venous thrombosis due to compression of the external iliac vein and artery by the reservoir of a three-piece inflatable penile prosthesis. **Deho' F, Henry GD, Marone EM, Sacca' A, Chiesa R, Rigatti P, and Montorsi F. Severe vascular complication after implantation of a three-piece inflatable penile prosthesis. J Sex Med 2008;5:2956–2959.**

Key Words. Penile Prosthesis; Erectile Dysfunction; Deep Venous Thrombosis

Introduction

Prosthetic devices are a well-established form of treatment for medically refractory erectile dysfunction (ED) [1–3]. Satisfaction rates cited for this approach are generally very high [4,5]. Although postoperative infection is the most feared complication of genitourinary prosthetic surgery [6], other complications have been described, including mechanical failure, cylinder crossover, tunica disruption, and urethral injury [7].

Only three articles in the literature reported vascular complications after implantation of a three-piece inflatable penile prosthesis (IPP) [8–10]. To our knowledge, concomitant acute arterial ischemia and deep venous thrombosis have not been described yet.

Case Report

M.F., a 67-year-old man with a body mass index of 30.4 kg/m² received his first rod prosthesis in 1992 for organic ED. Past medical history was negative for coronary artery disease and he referred to being a smoker in the past. Being unsatisfied with his erections, in 1995, he received an IPP (AMS 700; American Medical Systems, Minnetonka, Minnesota, USA) through an infrapubic approach. This device presented a mechanical failure after 3 years

(1998) and was substituted with a new one (AMS CX plus with intraperitoneal reservoir). The patient presented to our department in September 2006 for a mechanical failure recurrence. After a thorough cardiac and anesthesiological assessment, an AMS 700 CX Inhibizone (18 + 2 cm) was placed through a penoscrotal approach and a new 100 cc reservoir was placed in the right space of Retius. The reservoir was placed in a blind fashion through the penoscrotal incision. During the surgery and in the early postoperative period no hypotensive episode or atrial fibrillation occurred.

On the evening after placement he complained of right lower limb edema and pain.

Physical examination suggested deep venous thrombosis (DVT) with acute onset of +3, pitting edema and critical limb ischemia with tibial pulseless. Color-coded duplex ultrasonography (DUS) showed thrombosis of the right external iliac vein and tight stenosis of the right external iliac artery. The patient was stabilized and heparin was started at therapeutic levels. Abdominal CT scan showed compression of the right external iliac artery and vein by the IPP (Figure 1).

A vascular surgeon was consulted and a Greenfield filter (Boston Scientific, Natick, MA, USA) was placed in inferior vena cava with a percutaneous left femoral approach during the night to prevent pulmonary embolism. The IPP was subsequently fully activated in order to decrease

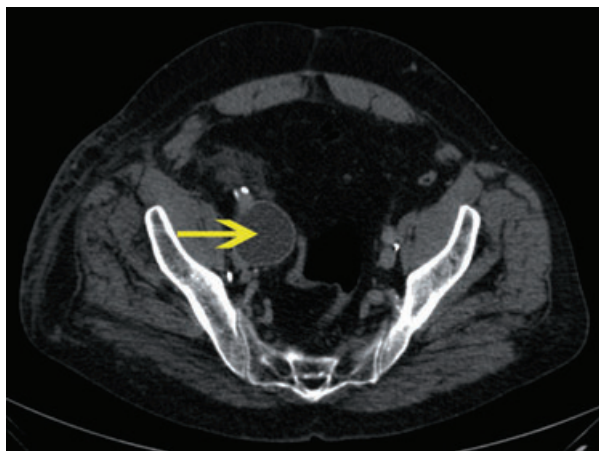


Figure 1 CT scan showed external compression of the right iliac vessels due to reservoir position (yellow arrow).

the arterial and venous compression. At DUS, the flow in the right common femoral artery was improved following the cylinders' inflation, however this was not enough to guarantee a valid arterial supply; critical right limb ischemia was still present. Thus, the patient was explored through a right inguinal incision and the 100 cc reservoir was removed. A new 65 cc reservoir was placed in an ectopic position during the same procedure. The intraoperative DUS showed normal flow in the right femoral artery with no signs of external compression of the right iliac artery. The patient was discharged from the hospital on the 7th postoperative day under warfarin at therapeutic levels with improvement of his lower extremity edema and without signs of critical limb ischemia. At the 12-month follow-up, he was satisfied with the prosthesis and no subsequent difficulties were reported.

Discussion

The reservoir's position, shown in Figure 1, suggests that it was erroneously placed in a more posterior position as compared to the usual one in the Retius space. We speculate that this might have occurred due to the body habitus of the patient, which made the maneuver difficult.

For revision of this kind of case, the surgical approach is either infrapubic or scrotal. According to published reports there is no evidence that one surgical approach maybe more effective than another [11]. In our experience, the transverse scrotal approach allows thorough exposure of the corpora cavernosa.

Placing the reservoir is a blind maneuver that requires attention. To place the reservoir safely, the bladder must be empty. The surgeon introduces the index finger into the penoscrotal incision and moves it up to the external inguinal ring. The finger in the ring protects the spermatic cord, and the surgeon uses closed Metzenbaum scissors placed medial to the finger just above the pubic bone. The scissors are inserted through the fascia transversalis that forms the floor of the external ring. When all layers of the fascia are penetrated, the surgeon can feel the back of the spina pubis and the catheter balloon in the empty bladder. A modified nasal speculum is used to maintain the opening in the fascia while the empty reservoir is inserted. The reservoir is then filled with normal saline, and a back pressure test is performed to avoid a high reservoir pressure, which contributes to autoinflation. A 65 mL reservoir should accommodate at least 50 mL of fluid at zero pressure, and a 100 mL reservoir should accommodate at least 85 mL. If the reservoir does not accommodate this much fluid, it likely is not in the true retropubic space [12,13].

We consider contraindications to the blind placement of the reservoir patients with ED after a radical cystectomy, presence of a renal transplant and a cement-like perivesical space resulting from an anastomotic leak after radical prostatectomy. In these cases we place the reservoir through a second, abdominal, skin incision.

In our opinion, the infrapubic approach has only one advantage that it allows the reservoir to be implanted under direct view. However, disadvantages of this approach include possible damage to the dorsal nerves of the penis with sensory loss, limited corporeal exposure, and lack of ability to fix the pump in the scrotum. Dorsal nerve injury with the infrapubic approach seldom occurs during a first implant procedure, when a scalpel is used to open the corpora. However, with revisions, an electrosurgical unit is usually used to make the corporotomy, and dispersion of current can cause nerve damage, possibly leading to sensory loss.

Some surgeons prefer to routinely use 100 cc reservoirs in order to decrease the risk of reservoir herniation. We routinely used a 65 cc reservoir if cylinder up to 18 cm length is placed, and in our series we did not report herniation of the reservoir.

To our knowledge, only three other reports are present in the literature concerning DVT after an IPP surgery, but this is the first time that acute arterial ischemia is reported (Table 1). Although rare, this complication should be considered. A

Table 1 Summary of published reports of vascular complications after penile prosthesis placement

	Patients (N)	Mean follow-up	Time since symptom presentation	Operating technique	Medical treatment	Vena cava filter	Complications
Flanagan et al. 1991 [8]	1	Not stated	2 years	Reservoir revision and repositioning in the Retius space	Heparin	No	None
da Justa et al. 2003 [9]	1	24 months	3 days	Reservoir revision and repositioning in the Retius space	Heparin	Yes	None
Brison et al. 2007 [10]	1	Not stated	4 days	Reservoir revision and thrombectomy	Heparin	Yes	None
Present series	1	7 months	12 hours	Reservoir revision and repositioning in ectopic position	Heparin + warfarin	Yes	None

CT scan and DUS were sufficient to diagnose the problem and plan surgical correction. Preoperative and intraoperative consultation with a vascular surgeon is mandatory in order to manage safely these vascular complications.

Corresponding Author: Federico Deho', MD, Urology Department San Raffaele Hospital, Via Olgettina 60 20132 Milan, Italy. Tel: +393474684005; Fax: +390226437298; E-mail: deho.federico@hsr.it

Conflict of Interest: None declared.

Statement of Authorship

Category 1

(a) Conception and Design

Federico Deho'; Gerard D. Henry; Enrico M. Marone; Antonino Sacca'; Roberto Chiesa; Patrizio Rigatti; Francesco Montorsi

(b) Acquisition of Data

Antonino Sacca'

(c) Analysis and Interpretation of Data

Federico Deho'; Enrico M. Marone

Category 2

(a) Drafting the Article

Federico Deho'; Antonino Sacca'; Enrico M. Marone; Gerard D. Henry

(b) Revising It for Intellectual Content

Roberto Chiesa; Patrizio Rigatti; Francesco Montorsi

Category 3

(a) Final Approval of the Completed Article

Federico Deho'; Francesco Montorsi; Gerard D. Henry; Antonino Sacca'; Enrico M. Marone; Roberto Chiesa; Patrizio Rigatti

References

- 1 Wilson SK, Delk JR, Salem EA, Cleves MA. Long-term survival of inflatable penile prostheses: Single surgical group experience with 2,384 first-time implants spanning two decades. *J Sex Med* 2007;4:1074-9.
- 2 Montorsi F, Rigatti P, Carmignani G, Corbu C, Campo B, Ordesi G, Breda G, Silvestre P, Giammusso B, Morgia G, Graziottin A. AMS three-piece inflatable implants for erectile dysfunction: A long-term multi-institutional study in 200 consecutive patients. *Eur Urol* 2000;37:50-5.
- 3 Kava BR, Yang Y, Soloway CT. Efficacy and patient satisfaction associated with penile prosthesis revision surgery. *J Sex Med* 2007;4:509-18. Epub Nov 6, 2006.

- 4 Akin-Olugbade O, Parker M, Guhring P, Mulhall J. Determinants of patient satisfaction following penile prosthesis surgery. *J Sex Med* 2006;3:743–8.
- 5 Natali A, Olianias R, Fisch M. Penile implantation in Europe: Successes and complications with 253 implants in Italy and Germany. *J Sex Med* 2008; 5:1503–12. Epub Apr 10, 2008.
- 6 Henry GD, Wilson SK, Delk JR 2nd, Carson CC, Silverstein A, Cleves MA, Donatucci CF. Penile prosthesis cultures during revision surgery: A multicenter study. *J Urol* 2004;172:153–6.
- 7 Brown ET, Saunders SE, Zaslau S. Penile prosthesis pump tubing erosion into urethra appearing as inability to catheterize: A case report. *J Sex Med* 2008; doi: 10.1111/j.1743-6109.2008.00868.x
- 8 Flanagan MJ, Krisch EB, Gerber WL. Complication of a penile prosthesis reservoir: Venous compression masquerading as a deep venous thrombosis. *J Urol* 1991;146:847–8.
- 9 da Justa DG, Bianco FJ Jr, Ogle A, Dhabuwala CB. Deep venous thrombosis due to compression of external iliac vein by the penile prosthesis reservoir. *Urology* 2003;61:462.
- 10 Brison D, Ilbeigi P, Sadeghi-Nejad H. Reservoir repositioning and successful thrombectomy for deep venous thrombosis secondary to compression of pelvic veins by an inflatable penile prosthesis reservoir. *J Sex Med* 2007;4:1185–7.
- 11 Montague DK, Angermeier KW. Surgical approaches for penile prosthesis implantation: Penoscrotal vs infrapubic. *Int J Impot Res* 2003;15(suppl 5):S134–5.
- 12 Montagne DK. Penile prosthesis implantation for end-stage erectile dysfunction after radical prostatectomy. *Rev Urol* 2005;7(suppl 2):S51–7.
- 13 Wilson SK. Pearls, pitfalls and perils of penile prosthesis implantation. In: Hellstrom W, ed. *Male infertility and sexual dysfunction*. New York: Springer-Verlag; 1996.