

Surgical Techniques

The Henry Mummy Wrap™ and the Henry Finger Sweep™ Surgical Techniques

Gerard D. Henry, MD

Regional Urology, Urology, 255 Bert-Kouns, Shreveport, LA, USA

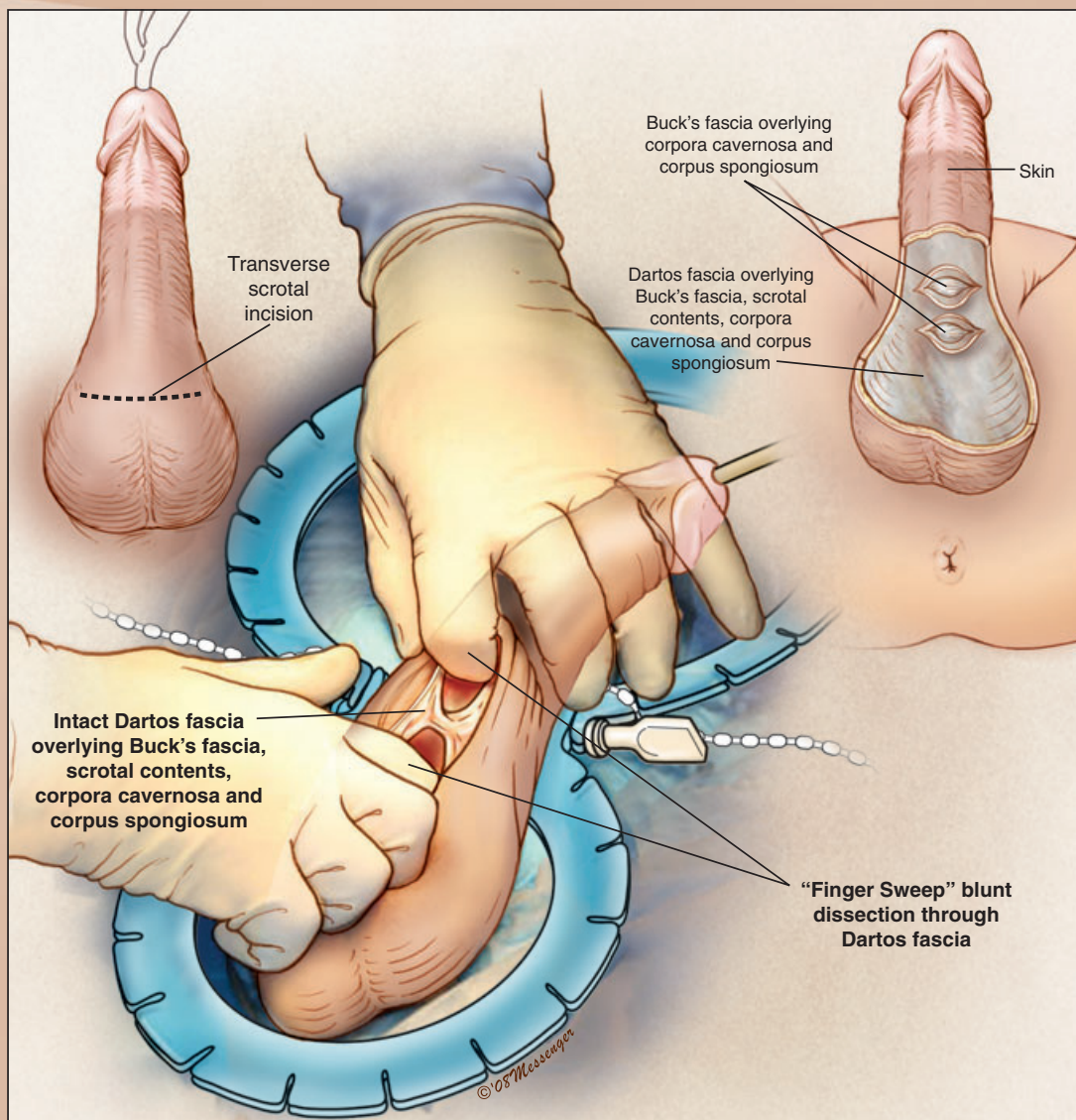


FIGURE 1

Traditionally, during the placement of a penile prosthesis, following the skin incision sharp dissection has been favored to expose the tunica albuginea. Such sharp dissection can be tedious, associated with bleeding and potential injury to the corpus spongiosum and urethra. The new "finger sweep" method is a safe and quick blunt dissection alternative. A small transverse incision is made 1–2 cm inferior to the penile scrotal junction. Two fingers are inserted inside the incision through the dartos layer. The fingertips are forcefully pushed down along the course of the corpora cavernosa "sweeping" and opening up the dartos layer until the tips are firmly on Buck's fascia. The dartos is a fascial plane covering scrotal contents and Buck's fascia overlying the three corpora.

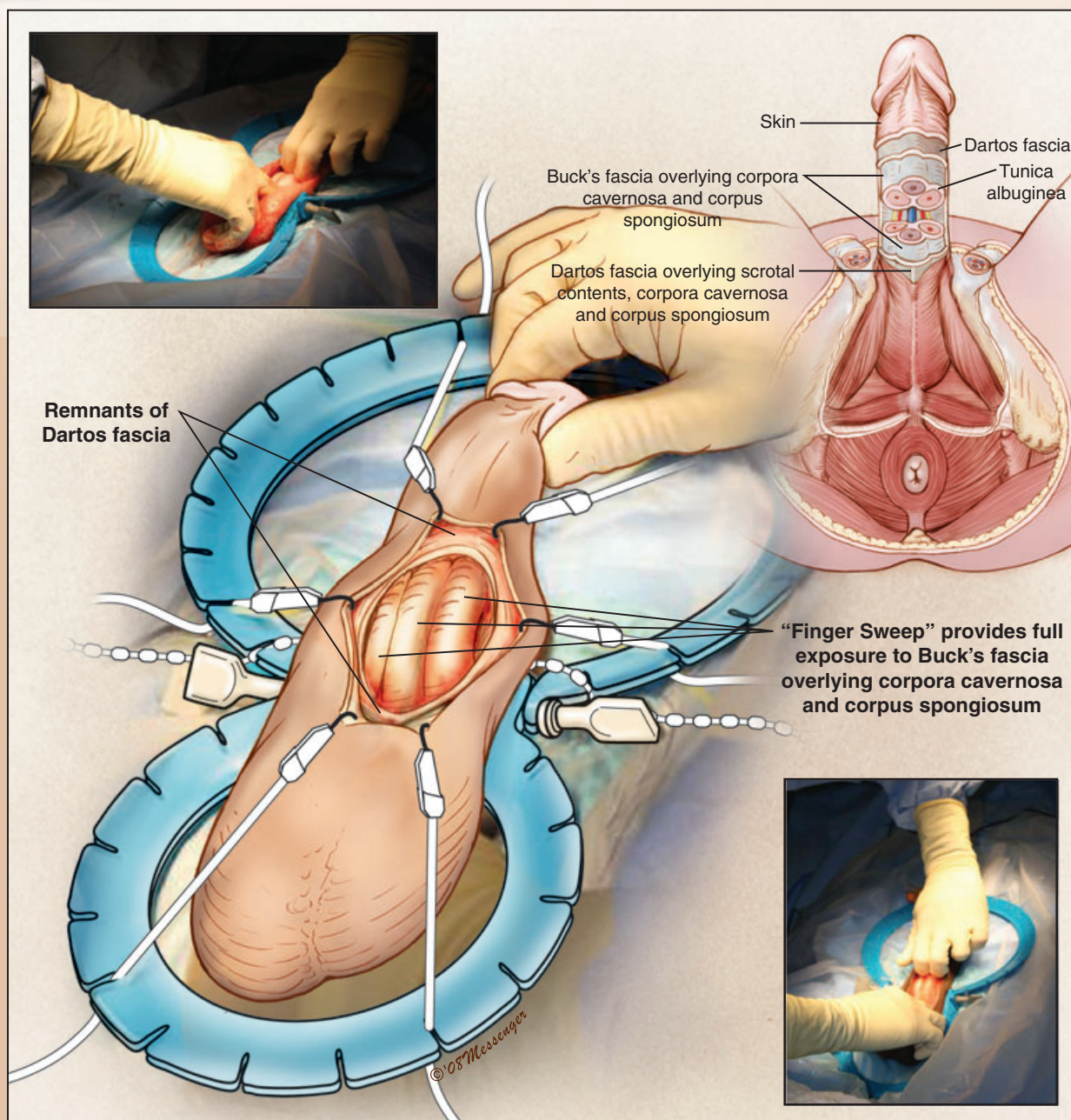


FIGURE 2

The fingers work like a rake with repeated sweeps in multiple locations along the horizontal line below the incision, cleaning off the dartos and then cleaning off Buck's fascia. Both hands can be used in opposite directions, for more direct power, continuing until the corpora cavernosa and corpus spongiosum are cleaned off anteriorly. Six stay hooks for the retractor are applied. The surgeon may proceed to cylinder implantation without additional exposure.

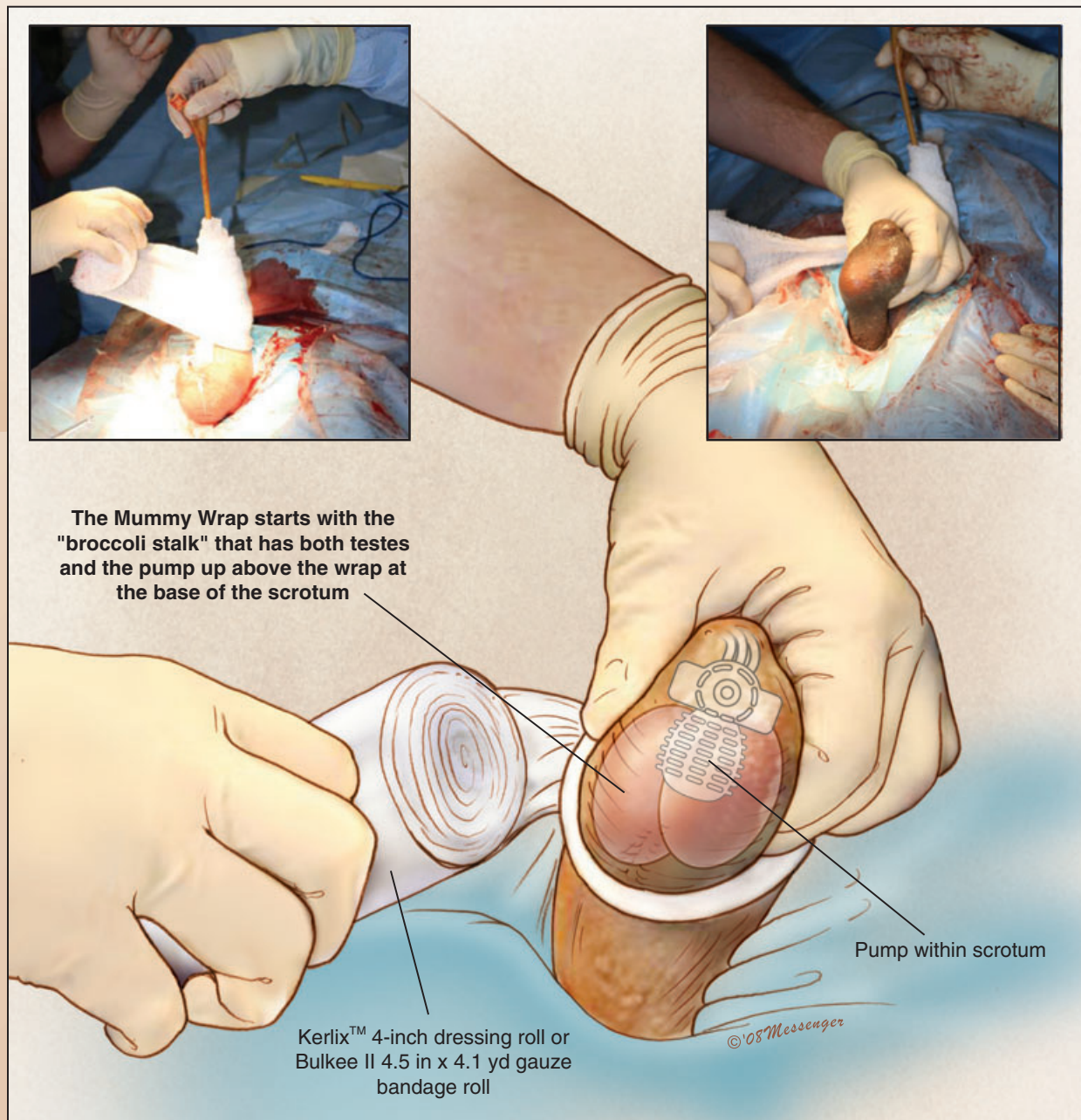


FIGURE 3

A mummy wrap is applied to decrease swelling and promote healing. The wrap maintains the pump in position for as long as the dressing is left on, as a capsule will start to form around the pump in the desired long-term position. The Henry Soft Cast wrap uses a non-sticky dressing, e.g., a Kerlix 4-inch dressing roll or Bulkee II 4.5 in x 4.1 yd gauze bandage roll (Medline Industries, Inc., Mundelein, IL, USA). Initially, the dressing is wrapped loosely, slowly winding all the way down the shaft of the penis. Next, the scrotum is elevated in a "broccoli stalk" fashion, making sure both testicles and the pump are pulled up. After winding the dressing around the base of the entire genitalia three times, the dressing is wrapped more tightly, and then only moderately, where dressing already exists. Obese patients, or those with a small tight scrotum can require several circumferential wraps around the base of the whole genitalia to ensure that the testicles and pump are pushed forward into the cast.

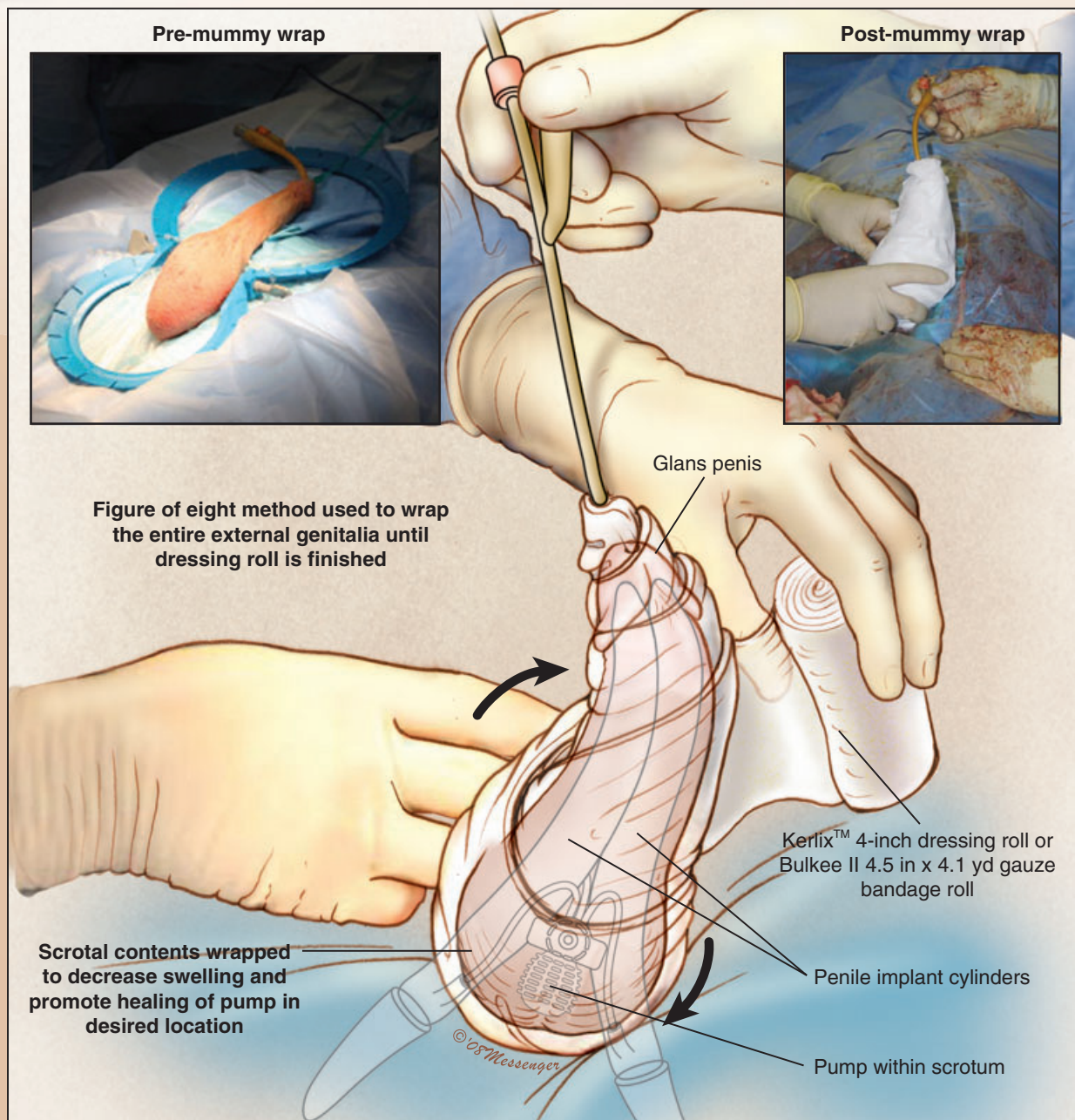


FIGURE 4

A “figure of eight” type of method is used to wrap the entire external genitalia until the dressing roll is finished. The soft cast that develops at the end of the wrap procedure resembles an orthopedic extremity ankle cast. After the dressing is placed, a soft cloth surgical tape, such as Medipore (3M, St. Paul, MN, USA), is applied around the soft cast, with minimal tape adherent to the patient’s skin. A Foley catheter can be left in place as long as the wrap is on, as some patients can have difficulty voiding with the soft cast. Typically, the dressing is removed the next day. For patients on anticoagulant therapy, or for other reasons, the wrap may be left on for 2 days. As there is no tape on the patient and no drain, removing the dressing is remarkably easy. If the inflatable penile prosthesis was left inflated, it is now very easy and much less painful to deflate, as there is essentially no swelling and the pump is easily palpated. Without expansion of the scrotum, there should be no hematoma while the dressing is in place.