

Historical Review of Penile Prosthesis Design and Surgical Techniques: Part 1 of a Three-Part Review Series on Penile Prosthetic Surgery

Gerard D. Henry, MD

Regional Urology, Urology Department, Shreveport, LA, USA

DOI: 10.1111/j.1743-6109.2008.01145.x

ABSTRACT

Introduction. Throughout history, many attempts to cure complete impotence have been recorded. Early attempts at a surgical approach involved the placement of rigid devices to support the natural process of erection formation. However, these early attempts placed the devices outside of the corpora cavernosa, with high rates of erosion and infection. Today, most urologists in the United States now place an inflatable penile prosthesis (IPP) with an antibiotic coating inside the tunica albuginea.

Aim. The article describes the key historical landmarks in penile prosthesis design and surgical techniques.

Methods. The article reviews and evaluates the published literature for important contributions to penile prosthesis design and surgical techniques.

Main Outcome Measures. The article reviews and evaluates the historical landmarks in penile prosthesis design and surgical techniques that appear to improve outcomes and advance the field of prosthetic urology for the treatment of erectile dysfunction.

Results. The current review demonstrates the stepwise progression starting with the use of stenting for achieving rigidity in the impotent patient. Modern advances were first used in war-injured patients which led to early implantation with foreign material. The design and techniques of penile prostheses placement have advanced such that now, more complications are linked to medical issues than failure of the implant.

Conclusions. Today's IPPs have high patient satisfaction rates with low mechanical failure rates. **Gerard D. Henry. Historical review of penile prosthesis design and surgical techniques: Part 1 of a three-part review series on penile prosthetic surgery. J Sex Med 2009;6:675–681.**

Key Words. Penile Prosthesis; Erectile Dysfunction; Penis; Impotence

Introduction

The earliest descriptions of erectile dysfunction (ED) can be found in ancient Egyptian hieroglyphics. Accounts are also found in the Old Testament, and the works of Hippocrates and Ovid [1]. Attempts at clarifying the causes of ED included congenital origins, diseases, and voluntary, and mental origins, as found in Hindu literature of the 8th century BC [2]. The early proposed remedies for ED included prayer, aphrodisiacs, herbal concoctions, and spiritual consultation [3].

This historical review concentrates on prosthetic surgical intervention, especially, the inflat-

able penile prosthesis (IPP) (see Table 1). The earliest implanted materials designed to improve or simulate erectile function included wooden sticks, either placed under the skin of the penis or into the urethra. With increased knowledge of human anatomy, autologous materials were implanted. Modern efforts to develop penile prostheses were driven largely by the need to repair war injuries [4]. The first detailed attempt at implantation to correct ED was done in 1936 by Bogoras, who reconstructed an amputated penis, with an abdominal tube pedicle graft (cited in Gee, 1975) [5]. To provide rigidity, Bogoras inserted a section of rib cartilage into the reconstructed

Table 1 Modern historical landmarks in penile prosthesis design and surgical technique

1930–1940s	Reconstructed penis, typically for war injuries had stents/ribs placed for rigidity [4–7]
1950–1960s	First artificial penile implants placed beneath Buck's fascia, outside corpora [8–10]
1966–1973	Artificial rods placed beneath the tunica albuginea (intracavernosally) [11–13]
1973	Brantley Scott introduces the IPP with high failure rates and complex implantation [22,23]
1974–1990s	Design improvements lower failure rates and simplify the implantation [14–21,24–34]
1996–2005	Salvage rescue and revision washout techniques combat infection [40,46–48]
2000–2002	Antibiotic coatings on the penile prosthesis appear to lower infection rates [35,36]

IPP = inflatable penile prosthesis.

penis. Frumkin, a Soviet surgeon who treated numerous penile amputations during World War II, built upon Bogoras' method [6]. Further development of autologous implantation [7] often resulted in stent extrusion or erosion, or significant curvature.

Early Implantation with Foreign Materials

The first artificial penile implants were made of acrylic, and placed beneath Buck's fascia, but outside the corpora cavernosum [8]; unfortunately, many patients experienced complications and implant extrusion. By 1964, silicone rubber penile implants were better tolerated, and less likely to induce infection [9]. In 1967, Pearman proposed using a unitary rigid rod of SilasticTM (Figure 1) [10], but by placing it under Buck's fascia, between the two corporal bodies, extrusion remained a frequent complication. When Pearman placed the prosthesis beneath the tunica albuginea, improved results were achieved [11]. Implantation of pros-

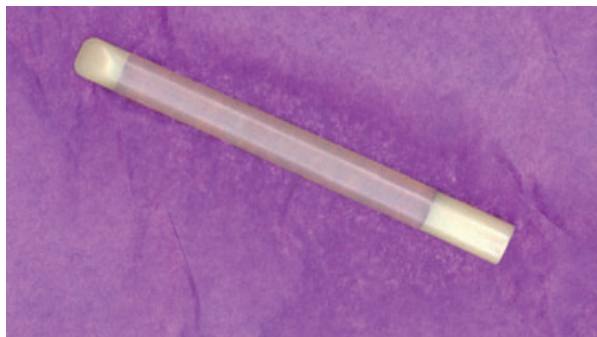


Figure 1 The Pearman penile prosthesis (Courtesy of the AUA Historical Library).

theses into the corpora cavernosa significantly advanced surgical technique and provided the basis for modern designs [12].

Beheri first documented success with intracavernosal placement of polyethylene rods in 700 patients in 1966 [13]. However, in 1973, the experience of Morales and colleagues with the Beheri-type rods involved frequent perforation and erosion. They constructed a larger, more flexible silicone implant filled with silicone gel [14], which reduced perforation and erosion risk, but the implants were susceptible to leaks and had short shelf lives. Also in 1973, the Small-CarrionTM prosthesis, with a silicone exterior and silicone sponge center, permitted filling of the corpus cavernosa, customized length of the prosthesis, and enhanced girth. Easier placement and higher mechanical reliability formed standards for malleable implants used for two decades [15].

Despite advances in design and placement, concealment remained a problem. In 1977, Finney developed the Flexirod, with a tapered distal tip for better glans stability, a soft hinge for improved concealment, and a trimmable tail [16]. The Flexirod had low complication rates, and device failure was extremely rare. In 1980, the Jonas prosthesis consisted of a "silicone penile prosthesis in which silver wires were embedded to allow for voluntary bending of the penis for urination and resting position and for straightening for intercourse." [17] This design also allowed easier implantation through an incision distal to the sulcus coronarius, under local anesthetic. The Omniphase was a mechanically activated penile implant that could be alternatively flaccid and rigid, depending on the tension of a supporting central cable. Nevertheless, the Omniphase suffered from breakage of this central cable with subsequent loss of penile rigidity [18,19]. Similarly, the Duraphase—an articulating type of semirigid rod that is bendable and provides good support to the erection—had the mechanical complication of cable breakage that would render the device nonfunctional [20,21].

Although the U.S. implant market favors inflatable prostheses, some circumstances require semirigid implants. Several malleable systems are available, including the 600 M and the 650 by American Medical Systems (AMS, Minneapolis, MN, USA). Both have a stainless steel, woven-wire center covered by a trimmable silicone elastomer sheath. Coloplast (Minneapolis, MN, USA) also offers the Genesis, with a single spiral silver wire core, and the Acu-Form, with a helical shape surrounding a central wire core, which allows for

greater flexibility and less spring-back. Currently, the Genesis is the only malleable penile prosthesis available on the market today with an antibiotic/hydrophilic coating.

Inflatable Prostheses

The first IPP, introduced in 1973 by F.B. Scott, a urologist at the Baylor College of Medicine [22], consisted of two nondistensible cylinders of DacronTM-reinforced silicone elastomer. A rectangular reservoir was controlled by one pump for inflation and one for deflation, placed in the scrotum. These original implants, manufactured and marketed by AMS, were used from February 1973 to August 1974 [23]. The prosthesis underwent several improvements: elimination of the DacronTM reinforcement, a single inflation-deflation pump, and a round, flat reservoir with a peripheral seam and expandable cylinders. This prosthesis was used until 1983, with only two changes: a seamless, spherical reservoir and rear tip extender option.

From 1983 to 1987, the AMS 700 model IPP was prominent, with added features including thicker cylinders, redesigned front and rear tips, polytetrafluoroethylene sleeves to help decrease wear, and a sutureless connector system [24]. In 1986, kink-resistant tubing (KRT) was added, permitting more forgiving measurements in tubing length and fewer complications. Wilson and colleagues reported on 395 patients implanted since 1977; those with original AMS prostheses had a 61% complication/revision rate at 3–11 years. Patients implanted after 1983 experienced only a 13% revision rate with follow-up to 4 years [25].

Because expansion of the AMS 700 cylinders was limited by the elastic property of patients' corpora cavernosa, cylinder aneurysms were frequent. To address this, in 1987, the modified 700 CX had a three-ply design, in which implant fluid was pumped into an inner silicone tubing that expanded against a silicone-covered woven fabric layer. Thus, expansion was limited by the fabric layer, not the corpora. In 2000, the addition of ParyleneTM to the cylinder significantly decreased friction. The AMS 700CX also incorporated several important changes in tubing design: a molded strain relief added to the KRT junction, color-coded KRT, and pre-connected cylinders and pump tubing. These changes decreased intraoperative confusion, failure rates, complications, and operative time. In 2000, Carson and colleagues published a multicenter study of 372

patients with the AMS 700CX. Mean mechanical reliability was $92.1 \pm 3.3\%$ after 3 years, and $86.2 \pm 4.6\%$ after 5 years, with postoperative infection and device malfunction in 3.2 and 17.5% of the cases, respectively [26]. In 2007, Wilson and colleagues reported a greater than 60% 15-year IPP survival rate at a single institution [27].

Further improvements included the AMS Tactile PumpTM, which minimizes finger slippage during inflation and facilitates patient identification of the deflation portion [28]. The 700 CXM prostheses were originally introduced by AMS in 1990 as a narrower version for use in smaller penises, although now they are used most often in patients with corporal fibrosis. The CXR was designed specifically for patients with corporal fibrosis, requires corporal dilation to 9 French, as compared to 11 French for the CXM.

In 1990, AMS began offering the 700 Ultrex, with a similar cylinder design as the 700 CX, but with a middle fabric cylinder layer that expands in diameter and length when inflated, limited by the elasticity of the patient's penis. In 1993, AMS strengthened the middle fabric layer to decrease the risk of tearing. A 2002 study from the Cleveland Clinic compared overall, mechanical, and cylinder survivals among 85 patients with the premodification Ultrex (group 1) and 52 with the postmodification device (group 2). The 5-year Kaplan–Meier estimates of overall, mechanical, and cylinder survivals were 64.7, 70.7, and 80.2%, respectively, in group 1; and 77.7 ($P = 0.23$), 93.7 ($P = 0.017$), and 96.2% ($P = 0.008$), respectively, in group 2. On long-term follow-up, the 1993 modification of the Ultrex cylinders appears to have significantly decreased the propensity of cylinder failure of the premodification device, although there was overall no significance in Kaplan–Meier estimator [29]. Recently, AMS changed the name of the Ultrex, now calling it the Length Girth Expansion (LGX) to reflect the smaller diameter proximal end for easier proximal placement and snap on rear tip extenders. In addition, AMS has produced the new momentary squeeze (MS) pump, where the deflate button is held only 3–4 seconds while it continues to deflate with a one-way valve to prevent auto-inflation (Figure 2). There are currently no published studies of the LGX or the MS pump. In 1994, AMS also introduced a two-piece IPP, the Ambicor, which has two cylinders connected to a small scrotal pump. The main advantage is that there is no reservoir placement, but the device does not inflate or deflate as well as the three-piece models.

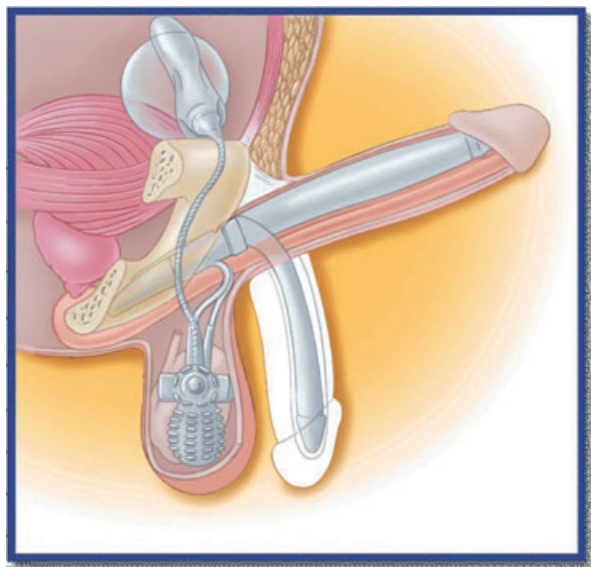


Figure 2 The AMS 700 series inflatable penile prosthesis (IPP) with the MS pump (Courtesy of AMS, Minneapolis, MN, USA).

In 1983, a three-piece IPP, the Mentor was launched, which contributed a significant advancement to implant technology. Mentor (now Coloplast) also changed the composition from silicone rubber to polyurethane and had an improvement to the cylinder design. Bioflex, the polyurethane substance, has seven times the tensile strength of silicone, without compromising biocompatibility and hemocompatibility [30]. With Bioflex, device failures from cylinder aneurysms or wear-induced abrasions were nearly eliminated, and the new device offered the widest available girth expansion. Through 1987, the Mentor IPP underwent several improvements: pump modification for easier valve identification, nylon-reinforced tubing to decrease the risk of kinks, cylinder base reinforcement to support the connection of tubing to cylinders, and a flange added to the snap-on connector clamps to improve stability [31]. In 1989, Mentor Corporation introduced the first connectorless, single pump-cylinder IPP, the α -1 (Alpha-1), which greatly improved reliability and reduced the risk of connector leakage. Lengthening and reinforcement of the tubing exiting the pump further improved 5-year survival rates from 75.3% for the original model to 92.6% (log rank $P < 0.0001$), and lowered the failure rate from 5.6% to 1.3% (log rank $P < 0.0001$) [32].

In 2000, Mentor added an enhanced reservoir with the Lock-out Valve™, which contains a “poplet” valve that does not allow fluid to exit

when pressure is applied to the reservoir. This was revolutionary because all previous reservoirs allowed water to freely flow in and out with abdominal pressure, potentially causing auto-inflation. In 2002, Wilson and colleagues published a study comparing 160 IPP patients with the lock-out valve to 339 patients with the original reservoir design. Only two patients (1.3%) with a lock-out valve complained of auto-inflation initially, with the problem resolved following further instruction. Among patients with the original reservoir, 11% reported auto-inflation, with 2% requiring operative correction [33].

A narrower model of the α -1 prosthesis, the α -1Narrow Base (NB), is now made by Coloplast. The α -1NB features 3.7-mm narrower cylinders, a narrower base, a more acute tubing exit angle, and 9-mm rear tip extenders, which make the NB more easily placed in patients with fibrotic or scarred corpora [34].

Antibiotic-Coated Prostheses

A significant innovation—InhibiZone™—was introduced by AMS in 2000, with Minocycline and Rifampin impregnated into the external silicone surfaces of the IPP. The antibiotics disperse in vivo, creating a zone of bacterial growth inhibition. In a 2004 study of 700 series prostheses, Carson reported on 2,261 men with the InhibiZone-coated IPP and a control group of 1,944 men with uncoated prostheses. Infection incidence was 0.28% in the treated group and 1.59% in the control group ($P = 0.0034$) after 60 days, and 0.68% and 1.61%, respectively ($P = 0.0047$), after 180 days. InhibiZone conferred an 82.4% lower infection rate than the control group after 60 days and a 57.8% lower rate after 180 days [35].

Mentor introduced the Titan in 2002, a hydrophilic substance that reduces bacterial adherence, and absorbs and diffuses antibiotics in which the implant is immersed intraoperatively (Figure 3). The Titan IPP offers the advantage that the surgeon chooses the preferred antibiotic for each individual. In 2004, Wolter and Hellstrom published a study comparing 1-year infection rates from the Titan IPP to Mentor’s previous α -1 prostheses. Data from 2,357 patients with the Titan IPP were compared with data from 482 patients with uncoated prostheses. The infection rates were 1.06% (25/2,357) for the Titan IPP and 2.07% (10/482) for the α -1 noncoated prosthesis ($P = 0.033$) [36].

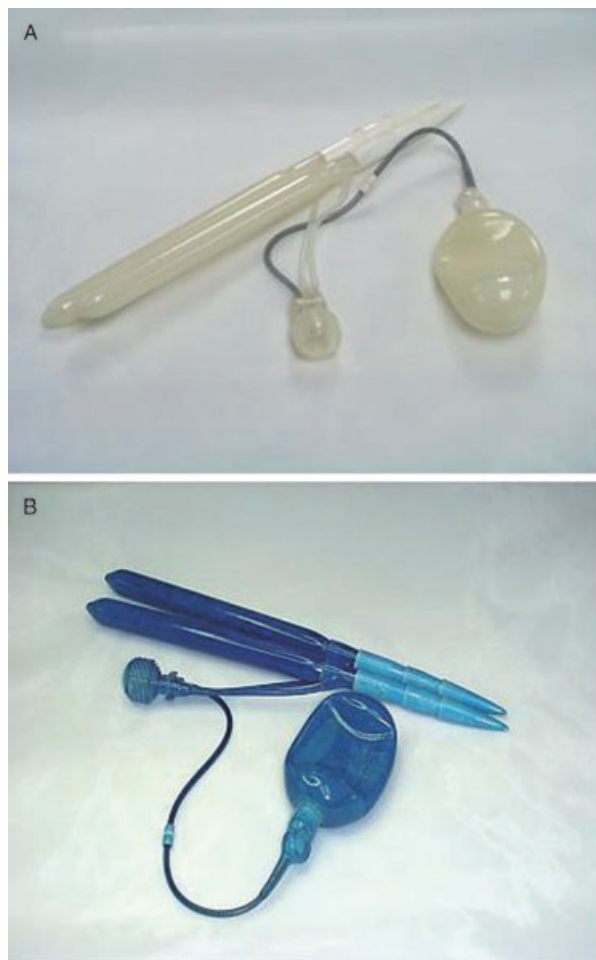


Figure 3 The Titan inflatable penile prosthesis (IPP) demonstrating the absorption properties of its hydrophilic coat (Courtesy of Coloplast Corporation, Minneapolis, MN, USA).

Improvements in Surgical Techniques and Biofilm

Infection has remained a significant complication in IPP surgery, especially for revision/replacement, which may be due to decreased host resistance, impaired antibiotic penetration due to capsule formation, and decreased wound healing related to scarring. Infection may be induced by contamination at surgery, as suggested by preoperative nasal swab cultures of *Staphylococci* that significantly correlate to postoperative infection rates [37]. Hematogenous late infections rarely occur [38]. Many bacteria produce a protective mucin coat or biofilm, which allows bacteria to survive at a lowered metabolic rate causing no overt symptoms [39]. Occasionally, bacteria are released from the biofilm, becoming free-floating or “planktonic,” and causing symptoms [39]. Antibiotics or the body’s defense mechanisms can kill planktonic bac-

teria, but within a biofilm, they cannot be eradicated except by implant removal and lavage of the implant spaces. In 1996, Brant et al. reported salvage success with removal of the infected device, and sequential antiseptic lavage to sterilize the implant space, followed by immediate reimplantation [40]. Many believe that the success of this revision washout technique is predicated on removal of the biofilm by the vigorous lavage. Extending this concept, the increased infection rate seen in clinically uninfected revisions may be due to activation of a biofilm formed after the original surgery. Theoretically, some aspect of the revision surgery stimulates the bacteria, causing them to become clinically active and causing symptoms.

Staphylococcus epidermidis is the most common organism found at removal of penile prostheses for infection [41]. Licht et al. found that 40% of uninfected prostheses had low colony counts of *S. epidermidis* [42]. None of the IPP patients with a negative culture at reoperation developed a subsequent infection. Therefore, ensuring a sterile environment at the time of revision/replacement may lower the rate of reoperation infection. Even better, using the revision washout and antibiotic-coated prosthesis could help ensure a sterile environment for the new implant, while the antibiotic elution addresses bacterial contamination at the time of the revision surgery.

Although the solutions used are antiseptic, it is possible that the most important part of the washout is the mechanical debridement of the bacteria/biofilm in the implant space. For example, betadine only becomes bactericidal when it dries. Furthermore, it is possible that some of the irrigants (i.e., hydrogen peroxide) cause tissue irritation or disruption, making patients more susceptible to infection. A future study might compare antiseptic solutions with normal saline as the washout irrigant.

Recent studies have shown that most implants have bacteria/biofilm on them at the time of revision surgery [43,44]. Therefore, if the entire implant is not removed, there is a possibility of reactivation of biofilm existing on the original implant’s retained components. However, because of occasional difficulty involved in removing the reservoir, removal of the reservoir should not be construed as the standard of care. If removal of the reservoir proves difficult and there is no evidence of biofilm on the pump and cylinders, the original reservoir could be retained. A recent study notes no added incidence of subsequent infection in a large series of retained reservoirs [45].

While the InhibiZone coating has been shown to reduce infection rates for primary surgeries, the effect is less dramatic among revision cases [46]. The amount of antibiotic used to coat the InhibiZone IPP is less than a single oral pill, potentially enough to lower infection rates in primary surgeries but apparently not enough to combat established biofilm. Combining revision washout with replacement with an antibiotic-coated IPP appears to lower infection rates and the author strongly suggests incorporating this technique into a prosthetic urologist's regimen for clinically uninfected revision/replacement cases. [46,47] Revision washout appears to lower implant capsule bacterial positivity rates, demonstrating the need for revision washout in clinically uninfected revision/replacement cases [48]. Patients enjoy good satisfaction rates after revision IPP surgery [49].

Conclusions

The search for a reliable surgical therapy for impotence has produced penile implants that yield high patient satisfaction and mechanical reliability rates. Enhancements in design and better surgical techniques have resulted in improved device survival rates. Future improvements may be aimed at ease of implantation, reduced morbidity, and improved patient satisfaction.

Acknowledgment

The author thanks Caroline J. Simmons for editorial contributions to the manuscript.

Corresponding Author: Gerard D. Henry, MD, Regional Urology LLC, 255 Bert Kouns—Industrial Loop, Shreveport, LA 71106, USA. Tel: (318) 683-0411; Fax: (318) 636-5883; E-mail: GDHenry@Hotmail.com

Conflict of Interest: Lecturer for Coloplast, American Medical Systems, Lilly, and Pfizer.

References

- Brendel OJ. The greco-roman world. In: Bowie T, Christenson CV, eds. Studies in erotic art. New York: Basic Books; 1970:38.
- Herman JR. Aphrodisiacs. In: Herman, JR, ed. Urology, a view through the retrospectoscope. New York: Harper & Row; 1973:43.
- Shah J. Erectile dysfunction through the ages. *BJU Int* 2002;90:433–41.
- Carson CC. History of urological prostheses. In: Carson CC, ed. Urologic prostheses: The complete practical guide to devices, their implantation, and patient follow up. Totowa, NJ: Humana Press; 2002:1.
- Gee WF. A history of surgical treatment of impotence. *Urology* 1975;5:401–5.
- Frumkin AP. Reconstruction of the male genitalia. *Am Rev Soviet Med* 1944;2:14–7.
- Bergman RT, Howard AH, Barnes RW. Plastic reconstruction of the penis. *J Urol* 1948;59:1174–86.
- Loeffler RA, Sayegh ES. Perforated acrylic implants in management of organic impotence. *J Urol* 1960;84:559–61.
- Lash H, Zimmerman DC, Loeffler RA. Silicone implantation: Inlay method. *Plast Reconstr Surg* 1964;34:75–80.
- Pearman RO. Treatment of organic impotence by implantation of a penile prosthesis. *J Urol* 1967;97:716–9.
- Pearman RO. Insertion of a silastic penile prosthesis for the treatment of organic sexual impotence. *J Urol* 1972;107:802–6.
- Daubert G. Coalition for the advancement of prosthetic urology: History, accomplishments, and continuing mission. *J Sex Med* 2006;3:976–8.
- Beheri GE. Surgical treatment of impotence. *Plast Reconstr Surg* 1966;38:92–7.
- Morales PA, Suarez JB, Delgado J, Whitehead ED. Penile implant for erectile impotence. *J Urol* 1973;109:641–5.
- Small MP, Carrion HM, Gordon JA. Small-Carrion penile prosthesis. *Urology* 1975;5:479–86.
- Finney RP. Finney flexirod prosthesis. *Urology* 1984;23:79–82.
- Jonas U, Jacobi JH. Silicone-silver penile prosthesis: Description, operative approach, and results. *J Urol* 1980;123:865–7.
- Levinson K, Whitehead ED. Omniphase penile prosthesis: Delayed bilateral central cable breakage. *J Urol* 1989;141:618–9.
- Huisman TK, Macintyre RC. Mechanical failure of Omniphase penile prosthesis. *Urology* 1988;31:515–6.
- Thompson IM, Rodriguez FR, Zeidman EJ. Experience with Duraphase penile prosthesis: Its use as replacement device. *Urology* 1990;36:505–7.
- Mulcahy JJ, Krane RJ, Lloyd LK, Edson M, Siroky MB. Duraphase penile prosthesis—Results of clinical trials in 63 patients. *J Urol* 1990;143:518–9.
- Scott FB, Bradley WE, Timm GW. Management of erectile impotence: Use of implantable inflatable prosthesis. *Urology* 1973;2:80–2.
- Fishman IJ, Scott FB, Light JK. Experience with inflatable penile prosthesis. *Urology* 1984;23:86–92.
- Montague DK, Angermeier KW. Inflatable penile prostheses: The American Medical Systems experience. In: Carson CC, ed. Urologic prostheses: The

- complete practical guide to devices, their implantation, and patient follow up. Totowa, NJ: Humana Press; 2002:179–90.
- 25 Wilson SK, Wahman GE, Lange JL. Eleven years' experience with the inflatable penile prosthesis. *J Urol* 1988;139:951–2.
 - 26 Carson CC, Mulcahy JJ, Govier FE. Efficacy, safety, and patient satisfaction outcomes of the AMS 700CX inflatable penile prosthesis: Results of a long-term multicenter study. AMS 700CX Study Group. *J Urol* 2000;164:376–80.
 - 27 Wilson SK, Delk JR, Salem EA, Cleves MA. Long-term survival of inflatable penile prostheses: Single surgical group experience with 2,384 first-time implants spanning two decades. *J Sex Med* 2007;4:1074–9.
 - 28 Delk JR, Knoll LD, McMurray J, Shore N, Wilson SK. Early experience with the American Medical Systems new tactile pump: Results of a multicenter study. *J Sex Med* 2005;2:266–71.
 - 29 Milbank AJ, Montague DK, Angermeier KW, Lakin MM, Worley SE. Mechanical failure of the American Medical Systems Ultrex inflatable penile prosthesis: Before and after 1993 structural modification. *J Urol* 2002;167:2502–6.
 - 30 Hackler RH. Mentor inflatable penile prosthesis: A reliable mechanical device. *Urology* 1986;28:489–91.
 - 31 Brooks MB. 42 months of experience with the Mentor inflatable penile prosthesis. *J Urol* 1988;139:48–9.
 - 32 Wilson SK, Cleves MA, Delk JR. Comparison of mechanical reliability of original and enhanced Mentor Alpha I penile prosthesis. *J Urol* 1999;162:715–8.
 - 33 Wilson SK, Henry GD, Delk JR, Cleves MA. The Mentor Alpha 1 penile prosthesis with reservoir lock-out valve: Effective prevention of auto-inflation with improved capability for ectopic reservoir placement. *J Urol* 2002;168:1475–8.
 - 34 Sadeghi-Nejad H. Penile prosthesis surgery: A review of prosthetic devices and associated complications. *J Sex Med* 2007;4:296–309.
 - 35 Carson CC. Efficacy of antibiotic impregnation of inflatable penile prostheses in decreasing infection in original implants. *J Urol* 2004;171:1611–4.
 - 36 Wolter CE, Hellstrom WJ. The hydrophilic-coated inflatable penile prosthesis: 1-year experience. *J Sex Med* 2004;1:221–4.
 - 37 Casewell MW. The nose: An underestimated source of *Staphylococcus aureus* causing wound infection. *J Hosp Infect* 1998;40:S3–11.
 - 38 Carson CC, Robertson CN. Late hematogenous infection of penile prosthesis. *J Urol* 1988;139:50–2.
 - 39 Stewart PS, Costerton JW. Antibiotic resistance of bacteria in biofilms. *Lancet* 2001;358:135–8.
 - 40 Brant MD, Ludlow JK, Mulcahy JJ. The prosthesis salvage operation: Immediate replacement of the infected penile prosthesis. *J Urol* 1996;155:155–7.
 - 41 Wilson SK, Delk JR. Inflatable penile implant infection: Predisposing factors and treatment suggestions. *J Urol* 1995;153:659–61.
 - 42 Licht MR, Montague DK, Angermeier KW, Lakin MM. Cultures from genitourinary prostheses at reoperation: Questioning the role of *Staphylococcus epidermidis* in periprosthetic infection. *J Urol* 1995;154:387–90.
 - 43 Henry GD, Wilson SK, Delk JR 2nd, Carson CC, Silverstein A, Cleves MA, Donatucci CF. Penile prosthesis cultures during revision surgery: A multicenter study. *J Urol* 2004;172:153–6.
 - 44 Silverstein AD, Henry GD, Evans B, Pasmore M, Simmons CJ, Donatucci CF. Biofilm formation on clinically non-infected penile prostheses. *J Urol* 2006;176:1008–11.
 - 45 Rajpurkar AD, Bianco FJ, Terlecki R, Dhuruwala CB. Fate of the retained reservoir after replacement of a three-piece penile implant. *J Urol* 2004;172:664–6.
 - 46 Henry GD, Wilson SK, Delk JR 2nd, Carson CC, Wiygul J, Tornehl C, Cleves MA, Silverstein A, Donatucci CF. Revision washout decreases penile prosthesis infection in revision surgery: A multicenter study. *J Urol* 2005;173:89–92.
 - 47 Abouassaly R, Angermeier KW, Montague DK. Risk of infection with an antibiotic coated penile prosthesis at device replacement for mechanical failure. *J Urol* 2006;176:2471–3.
 - 48 Henry GD, Carson CC, Wilson SK, Wiygul J, Tornehl C, Cleves MA, Simmons CJ, Donatucci CF. Revision washout decreases implant capsule tissue positivity: A multicenter study. *J Urol* 2008;179:169–72.
 - 49 Kava BR, Yang Y, Soloway CT. Efficacy and patient satisfaction associated with penile prosthesis revision surgery. *J Sex Med* 2007;4:509–18.